

Case Report

Persistent Metastatic Thyroid Carcinoma

Ghobad Azizi^{1*}, Michelle Lewis Mayo¹, Yasmin Azizi¹, James Keller², Carl Malchoff³

¹Wilmington Endocrinology, PA, ²Wilmington Pathology Associates, Wilmington, NC, ³University of Connecticut, Farmington, CT, USA

Abstract

The decision to biopsy small thyroid nodules (TNs) is controversial. Careful ultrasound (US) evaluation with shear wave elastography (SWE) of TN and cervical lymph nodes (LNs) may aid in the decision to biopsy and subsequently influence the extent of surgery. A 46-year-old female presented with TNs and hypothyroidism. Her target TN in the left lobe measured 4.8 mm × 4 mm × 4 mm. Fine needle aspiration biopsy of the left TN and a left neck level 6 LN was diagnostic for papillary thyroid carcinoma. In the left lateral neck posterior to the jugular vein, there was a LN with possible microcalcifications that could not be sampled due to vascular proximity. SWE examination showed high velocity suspicious for metastatic disease. In summary, risk stratification for small TNs and cervical LNs can be difficult. SWE can provide valuable information for assessing the risk for malignancy.

Keywords: Lymph node, shear wave elastography, thyroid carcinoma, thyroid nodule, ultrasound

INTRODUCTION

Performing fine-needle aspiration biopsy (FNAB) of thyroid nodules (TNs) <10 mm is controversial. The American College of Radiology (ACR) recently released a guideline for TN management called ACR-TIRADS or Thyroid Imaging Reporting and Data Systems, to assess the risk for thyroid cancer.^[1] TIRADS risk stratification model is primarily based on B-mode ultrasound (US) features and the size of the TN. This guideline does not recommend FNAB for any TN <10 mm regardless of other risk factors for malignancy. In addition, it does not address neck mapping or elastography.^[1]

CASE REPORT

A 46-year-old female was referred for TN and hypothyroidism due to autoimmune thyroiditis. This patient gave informed consent for this case report. Her thyroid US showed bilateral small TNs, <10 mm. Her left TN measured 4.8 mm × 4 mm × 4 mm [Figure 1a]. This TN had worrisome US features including irregular margins. Her neck US visualized a small left paratracheal (level 6) lymph node (LN) measuring 5.6 mm × 3 mm × 4.4 mm that appeared partially cystic [Figure 1b]. In addition, there was

an enlarged LN measuring 17 mm × 4 mm × 5 mm with possible microcalcifications [Figure 2a] in the left lateral neck posterior to the jugular vein [Figure 2b]. Shear wave elastography (SWE) velocity measurements of the LN were 6.59 m/s and 5.32 m/s [Figure 3]. The US used was a LOGIQ E9 (GE Ultrasound, Milwaukee, WI, USA).

The patient underwent FNAB of the 4.8 mm left TN due to irregular margins. Her left neck level 6 LN was also biopsied due to complex, cystic nature of the node. The FNAB cytopathology for both lesions was read as malignant (Bethesda Category VI). The left lateral LN could not be sampled due to the proximity of the jugular vein.

The patient underwent total thyroidectomy with central and left lateral neck dissection at a tertiary care center. Her surgical pathology report indicated multifocal bilateral papillary thyroid carcinoma. The largest focus in the right lobe was 3 mm, and the largest focus in the left lobe was 5 mm, corresponding with her biopsied TN in the left lower pole. Overall, 18 LNs were resected, and one positive LN in the left paratracheal area was reported. The location of this LN corresponded with her FNAB

Address for correspondence: Dr. Ghobad Azizi,
Wilmington Endocrinology, PA, 1717 Shipyard Boulevard, Suite 220,
Wilmington, NC 28403, USA.
E-mail: azizi@wilmingtonendo.com

Received: 15-08-2019 Revised: 11-09-2019 Accepted: 28-09-2019 Available Online: 10-12-2019

Access this article online

Quick Response Code:



Website:
www.jmuonline.org

DOI:
10.4103/JMU.JMU_81_19

This is an open access journal, and articles are distributed under the terms of the Creative Commons Attribution-NonCommercial-ShareAlike 4.0 License, which allows others to remix, tweak, and build upon the work non-commercially, as long as appropriate credit is given and the new creations are licensed under the identical terms.

For reprints contact: WKHLRPMedknow_reprints@wolterskluwer.com

How to cite this article: Azizi G, Mayo ML, Azizi Y, Keller J, Malchoff C. Persistent metastatic thyroid carcinoma. J Med Ultrasound 2020;28:111-3.

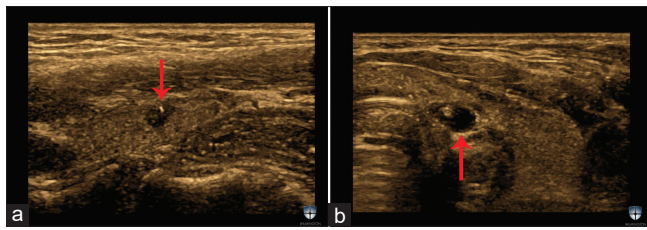


Figure 1: (a) A left thyroid nodule measuring 4.8 mm × 4 mm × 4 mm. This thyroid nodule is solid, hypoechoic with one focus of microcalcification and irregular margins. (b) A left paratracheal lymph node at level 6, measuring 5.6 mm × 3 mm × 4.4 mm. This lymph node has cystic component and calcifications

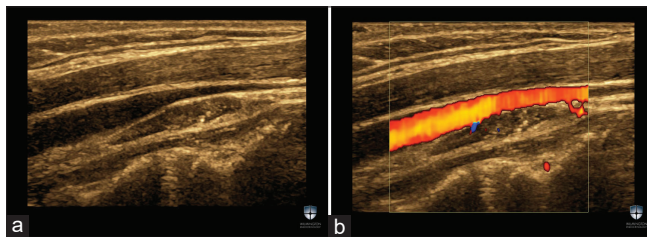


Figure 2: (a) A lymph node in the left neck level 4 measuring 17 mm × 4 mm × 5 mm. (b) This lymph node was located in the left lateral neck, posterior to the left jugular vein. We were unable to perform fine-needle aspiration biopsy of this lymph node because it was located in the posterior aspect of the left jugular

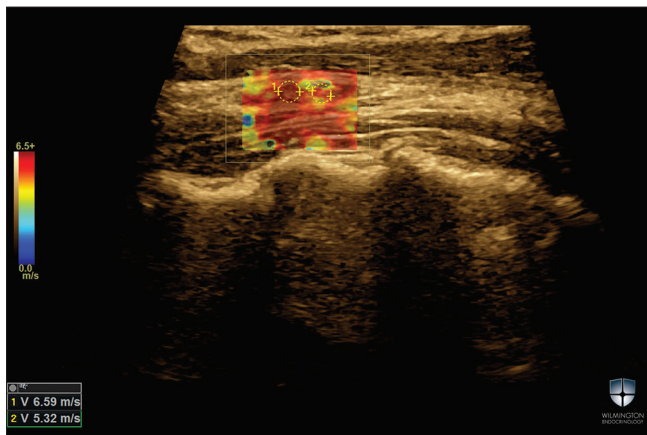


Figure 3: Qualitative and quantitative shear wave image of the lymph node. Shear wave velocity measurements of the lymph node were 6.59 m/s and 5.32 m/s. We were unable to perform fine-needle aspiration biopsy of this lymph node because it was located in the posterior aspect of the left jugular

finding. Her surgical pathology did not identify any metastatic LN in the left lateral neck.

Seven weeks after her surgery, while on a low iodine diet for 2 weeks, she underwent Thyrogen-stimulated I-123 scanning with single-photon emission computed tomography (CT). There was no abnormal activity in the left neck. She was immediately treated with 100 mci of I-131. Her postablation scan also showed no abnormal activity in the central or lateral neck.

Six months after her initial surgery, her thyroglobulin (TG) level was 4 ng/mL; however, her TG antibody was elevated at 1.9 IU/mL (normal range <0.9 IU/mL). TG and TG antibody were measured with radioimmunoassay by the Beckman Coulter Methodology by Lab Corp (LabCorp Esoterix Inc, Calabasas Hills, CA).

Her post-surgical neck ultrasound again demonstrated the 17 mm × 4 mm × 5 mm LN with possible microcalcifications in the left lateral neck, posterior jugular area. This LN could not be accessed for FNAB due to jugular vein proximity. The patient had a magnetic resonance imaging study of the neck soft tissue that did not report any abnormal findings and only indicated multiple benign-appearing small LNs. After considerable debate, the patient underwent a lateral neck exploration to remove the target LN. The pathology of the second neck dissection showed one of the five LNs involved by metastatic carcinoma.

DISCUSSION

Recently, ACR released a guideline for TN management, ACR-TIRADS, or Thyroid Imaging Reporting and Data Systems that is currently being used to assess the risk for thyroid cancer.^[1] The TIRADS reporting system has been applied to stratify the risk of malignant TN primarily based on the size and B-mode US features. The ACR modified and quantitated the TIRADS criteria but does not recommend FNAB for any TN < 10 mm regardless of malignancy risk. In addition, it does not address neck mapping or elastography.^[1] This case illustrates many of the challenges of TN management and the difficulties in assessing cervical LNs and the weakness of the current ACR-TIRADS system for evaluating TNs. In addition, this particular case also indicates that size of a TN might not be the most important factor in predicting the metastatic potential of a TN. The largest left TN measured only 4.8 mm in diameter, and yet, this patient had metastatic disease in the left neck level 6 and left lateral neck LNs.

We demonstrate here that SWE can be an added value to B-mode US in diagnosing malignancy in suspicious cervical LNs. Several recent publications using SWE showed good results in differentiating between benign and malignant cervical LNs.^[2-5] The extent of surgery can be modified with evaluation of cervical LN for malignancy before having surgery.

In the presented case, recommending a second surgery was difficult due to many factors. First, the original surgery was extensive, and only one of 18 resected LNs was malignant. Second, the remaining target LN could not be biopsied due to the vascular proximity, located in the posterior aspect of the left jugular vein. Third, serum TG remained detectable 6 months after surgery and radioactive iodine ablation. Fourth, the absence of radioactive iodine uptake in the left lateral neck region on I-123 whole body scan. A second surgery was ultimately recommended due to worrisome B-mode US features, including possible microcalcifications

and abnormal SWE examination, indicating high shear wave velocity (SWV).

In a previous published prospective study in the journal, *Ultrasound in Medicine and Biology*, it was demonstrated that in a single cutoff analysis for predicting malignancy in a cervical LN, a maximum SWV of 2.93 m/s had the best sensitivity of 92.59%.^[2] The specificity, positive predictive value, and negative predictive value were 75.46%, 48.54%, and 97.6%, respectively.^[2] B-mode US LN characteristics of cystic content and calcifications predicted malignancy in LNs with a high specificity; however, these features are not common, so the sensitivity was low in our study with 270 cervical LN.^[2] The sensitivity of predicting cancer for cystic content and calcification was 22.22% and 16.67%, respectively.^[2] These observations were useful in the management of this patient.

Performing FNAB of TNs <10 mm is controversial; however, if we had followed the ACR-TIRADS guidelines, this case of metastatic papillary thyroid carcinoma would not have been diagnosed.

CONCLUSION

This case illustrates the importance of LN evaluation at the time of identification of TNs and confirms the utility of SWE for the identification of small thyroid cancers and LNs with high probability for malignancy. All patients with abnormal TN biopsy should have neck mapping before surgery.

Acknowledgments

We would like to thank the Wilmington Endocrinology staff, especially Jessica Farrell for her assistance with this case report.

Declaration of patient consent

The authors certify that they have obtained all appropriate patient consent forms. In the form the patient(s) has/have given his/her/their consent for his/her/their images and other clinical information to be reported in the journal. The patients understand that their names and initials will not be published and due efforts will be made to conceal their identity, but anonymity cannot be guaranteed.

Financial support and sponsorship

Nil.

Conflicts of interest

There are no conflicts of interest.

REFERENCES

1. Middleton WD, Teefey SA, Reading CC, Langer JE, Beland MD, Szabunio MM, *et al.* Multiinstitutional analysis of thyroid nodule risk stratification using the American College of Radiology thyroid imaging reporting and data system. *AJR Am J Roentgenol* 2017;208:1331-41.
2. Azizi G, Keller JM, Mayo ML, Piper K, Puett D, Earp KM, *et al.* Shear wave elastography and cervical lymph nodes: Predicting malignancy. *Ultrasound Med Biol* 2016;42:1273-81.
3. Desmots F, Fakhry N, Mancini J, Reyre A, Vidal V, Jacquier A, *et al.* Shear wave elastography in head and neck lymph node assessment: Image quality and diagnostic impact compared with B-mode and Doppler ultrasonography. *Ultrasound Med Biol* 2016;42:387-98.
4. Choi YJ, Lee JH, Lim HK, Kim SY, Han MW, Cho KJ, *et al.* Quantitative shear wave elastography in the evaluation of metastatic cervical lymph nodes. *Ultrasound Med Biol* 2013;39:935-40.
5. Cheng KL, Choi YJ, Shim WH, Lee JH, Baek JH. Virtual touch tissue imaging quantification shear wave elastography: Prospective assessment of cervical lymph nodes. *Ultrasound Med Biol* 2016;42:378-86.